



Efficacy of Individualized Homoeopathic in the Treatment of Psoriasis: A Case Report

Dr Neha Nagar, Dr Ravi Kumar Poswal

ABSTRACT

Psoriasis is a chronic, non communicable, painful, disfiguring and disabling disease for which there is no cure and with great negative impact on patients' quality of life. It can occur at any age. Treatment of psoriasis is still based on controlling the symptoms. Topical and systemic therapies as well as phototherapy are available. In practice, a combination of these methods is often used. The need for treatment is usually lifelong and is aimed at remission.¹ A case with psoriatic patches all over the body since 4 years with itching along bleeding from cracks is discussed here. The present case was completely cured after taking regular treatment for one and a half years with individualized homeopathic medicine Sulphur 200. Homoeopathy has always been a safe and cost effective treatment in skin diseases.

Keywords: psoriasis, homoeopathy, autoimmune, sulphur

Abbreviations: Psoriasis Pustulosa Palmoplantaris (PPP), Acrodermatitis Continua of Hallopeau (ACS), Thrice daily (TDS)

INTRODUCTION

Psoriasis is a chronic autoimmune and non-communicable inflammatory disease of skin and joints. The word psoriasis comes from a Greek word "Psora" which means being itchy and "iasis" means a condition.¹

It is characterized by having sharply demarcated scaly, red, coin-sized skin lesions most often on the elbows, knees, scalp, hands and feet. Symptoms include itching, irritation, stinging and pain. Rarely, the entire skin surface of the body may be involved.¹

Clinical Classification-

Psoriasis Vulgaris

About 90% of psoriasis cases correspond to chronic plaque-type psoriasis. The classical clinical manifestations are sharply demarcated, erythematous, pruritic plaques covered in silvery scales. The plaques can coalesce and cover large areas of skin. Common locations include the

trunk, the extensor surfaces of the limbs, and the scalp.^{1,2}

Inverse Psoriasis

Also called flexural psoriasis, inverse psoriasis affects intertriginous locations, and is characterized clinically by slightly erosive erythematous plaques and patches.

Guttate Psoriasis

Guttate psoriasis is a variant with an acute onset of small erythematous plaques. It usually affects children or adolescents, and is often triggered by group-A streptococcal infections of tonsils. About one-third of patients with guttate psoriasis will develop plaque psoriasis throughout their adult life.^{1,2}

Pustular Psoriasis

Pustular psoriasis is characterized by multiple, coalescing sterile pustules. Pustular psoriasis can be localized or generalized. Two distinct localized phenotypes have been described: psoriasis

pustulosa palmoplantaris and acrodermatitis continua of hallopeau. Both of them affect the hands and feet; PPP is restricted to the palms and soles, and ACH is more distally located at the tips of fingers and toes, and affects the nail apparatus. Generalized pustular psoriasis presents with an acute and rapidly progressive course characterized by diffuse redness and subcorneal pustules, and is often accompanied by systemic symptoms.¹

Homoeopathy in Psoriasis

Recently homoeopathy has gained importance due to its advantages like being cost effective, no side effects etc. Homoeopathy treats the physical and mental symptoms of patients rather than the diseases or its effects and it completely eliminates the rashes. Studies have proved that homoeopathy is successfully used in the management of psoriasis and may not require maintenance treatment, following remission.

CASE REPORT

A 28 year old male working as a manager in private company was reported in outpatient department (OPD) of Bakson Homeopathic Medical College & Hospital, complained of psoriatic patches all over the body with intolerable itching with bleeding from cracks since 4 years. He got aggravation by bathing and touch. He felt very helpless because, he is taking allopathic treatment for the same for a longer period but got no relief and now he wanted to take homeopathic treatment for his complaint.

Past History

In the past he had suffered from typhoid fever at the age of 7 years, took ayurvedic treatment and recovered. He also suffered from pneumonia at the age of 16 years which was fully cured after taking homoeopathic treatment.

Family History

His father had a history of hypertension.

His mother had a history of rheumatoid arthritis.

Physical Generals

His appetite was increased even after eating food,

he had an extreme craving for warm drinks, and his thermal reaction was chilly. He preferred to eat potato on daily basis and his bowel movements were quite irregular, feels constipated, hard stool alternating with soft stool. His perspiration increased mainly while writing.

Mental Generals

He was very calm and mild in nature. He was very sad and depressed about his condition. He said he felt very embarrassed to meet peoples or even to attend office also. He also said that he easily got offended by slightest things done by others.

General Survey

The patient was cooperative; patient had peculiar stooped shoulders, cyanosis, clubbing or jaundice not detected.

DIAGNOSIS

Psoriasis vulgaris

On detailed case taking and analysis, the symptoms of mental general as well as physical generals and particular symptoms were considered for repertorisation.

The symptoms considered for the analysis and evaluation of the case were as follows-

- 1- Patient was very mild and calm in nature
- 2- He was very sad and depressed about his condition while narrating his complaints.
- 3- Felt helpless
- 4- Embarrassed to attend office and also to meet peoples.
- 5- Aggravation from others advises, got easily offended.
- 6- Desire to escape from current situation
- 7- Appetite increased; want to eat food even after eating also
- 8- Craving for warm drinks
- 9- Craving for potato
- 10- Perspiration mainly writing during.
- 11- Bowel irregular, Constipation Hard stool alternating with soft stool
- 12- Chilly patient

Case Report

- 13- Psoriatic Patches all over the body with cracks and bleeding.
- 14- Aggravation from bathing

- 15- Aggravation from touch
- 16- Patient had stooped shoulder

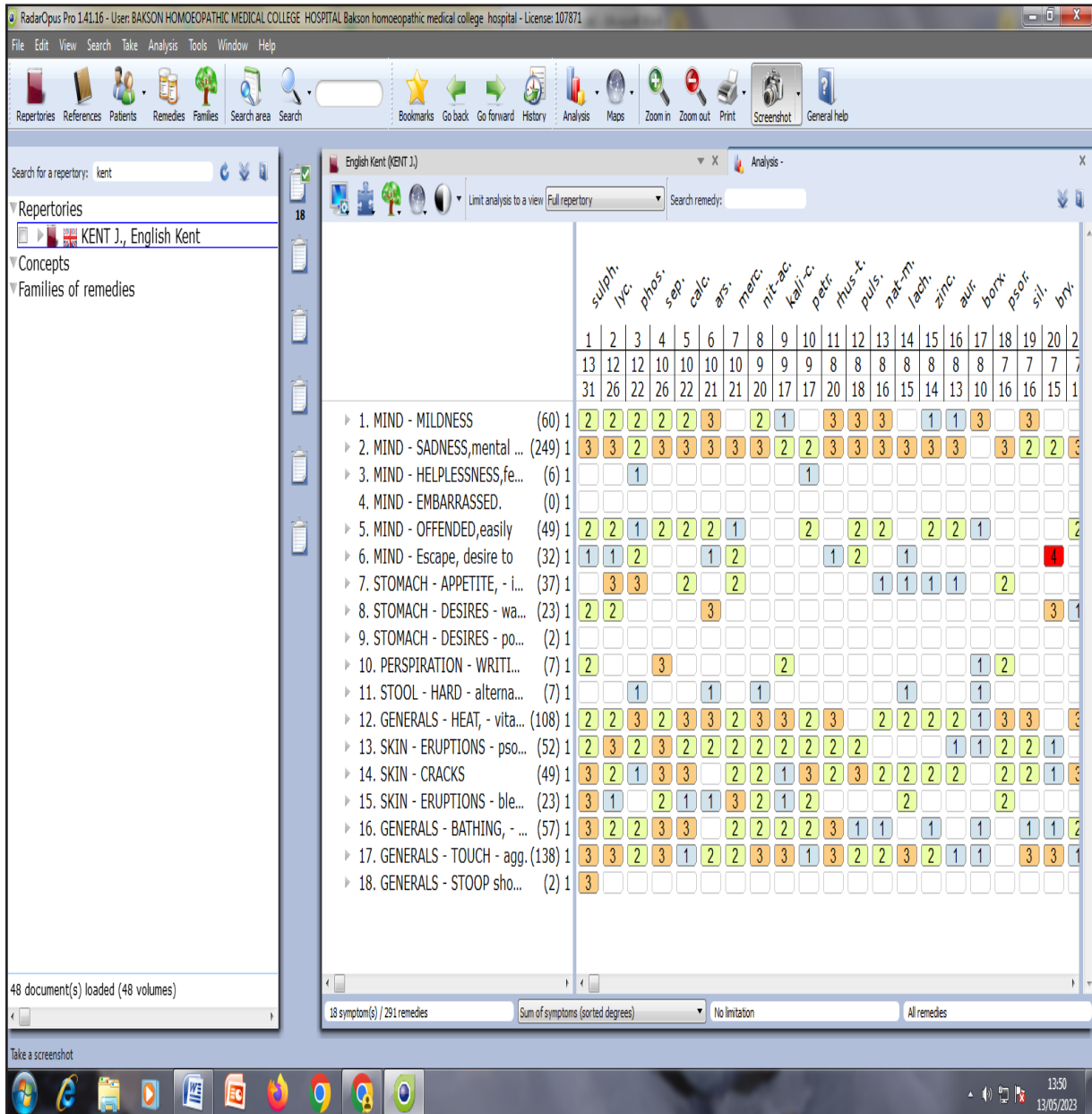


Figure-1- Repertorization Sheet