



International Journal of Homoeopathic Sciences

E-ISSN: 2616-4493

P-ISSN: 2616-4485

www.homoeopathicjournal.com

IJHS 2023; 7(2): 492-498

Received: 15-05-2023

Accepted: 10-06-2023

Dr. Nagar Neha

Assistant Professor,
Department of Repertory,
Bakson Homoeopathic Medical
College & Hospital, Greater
Noida, Colony Mayur Vihar,
Phase- 3, Delhi, India

Dr. Poswal Ravi K

Associate Professor,
Department of Materia
Medica, Bakson Homoeopathic
Medical College & Hospital,
Greater Noida, Uttar Pradesh,
India

Dr. Kumar Ajay

Assistant Professor,
Department of Paediatrics,
Bakson Homoeopathic Medical
College & Hospital, Greater
Noida, Uttar Pradesh, India

Singhal Kanak

Intern, Bakson Homoeopathic
Medical College & Hospital,
Greater Noida, Uttar Pradesh,
India

Corresponding Author:

Dr. Nagar Neha

Assistant Professor,
Department of Repertory,
Bakson Homoeopathic Medical
College & Hospital, Greater
Noida, Colony Mayur Vihar,
Phase- 3, Delhi, India

Usefulness of Homeopathic treatment in Tinea faciei: A case series

Dr. Nagar Neha, Dr. Poswal Ravi K, Dr. Kumar Ajay and Singhal Kanak

DOI: <https://doi.org/10.33545/26164485.2023.v7.i2h.872>

Abstract

Tinea faciei is a common fungal infection that mimics many other annular lesions. By this case report aimed to show the “Usefulness of Homeopathic treatment in tinea faciei. Case Summary: Three cases of ring worm i.e tinea faciei successfully treated with individualized homeopathic medicine. All three cases were reported at Vedika Homoeo & Yoga clinic. The first case was of 38 year old female patient complaints of ring worm on Left side of cheek since 1 year with remarkable redness with burning sensation .The second case was of 10 year old boy complaints of lesions on right side of face since 6 months. In the third case, 5 year old boy complaints of ring worm on face since 1 year. All three cases were treated with individualised homeopathic medicine after case taking and repertorization. All these cases were followed up regularly and they get cured within 3 months of regular treatment. Common remedies include calcarea carbonica, Arsenic album and Sulphur. This case series shows positive results of homoeopathy in the treatment of Tinea faciei.

Keywords: Tinea faciei, ring worm, homoeopathy, dermatophytes, repertorization

Introduction

Tinea corporis, also known as ‘ringworm’, is a superficial dermatophyte infection of the skin, other than on the hands (tinea manuum), feet (tinea pedis), scalp (tinea capitis), bearded areas (tinea barbae), face (tinea faciei), groin (tinea cruris), and nails (onychomycosis or tinea unguium) [1].

Tinea faciei accounts for 3 to 4% of all cases of tinea corporis. It occurs worldwide but has a predilection for tropical humid climates [2]. It may occur at any age, but two peaks may be observed: in childhood with a male prevalence, and in adults with a female prevalence [3, 4]. Females are affected more frequently than males because dermatophyte infections on the bearded areas of males are often diagnosed as tinea barbae, whereas in females they are more likely to be diagnosed as tinea faciei [2]. Many lesions progress over more than 6 months and even up to 2 years before they are diagnosed [4]. The incubation period is 1–3 weeks [5].

Clinical Presentation

A round lesion that may be expanding is discovered by a caretaker or the patient. The area may be mildly pruritic [6]. Infection typically occurs from direct contact of the healthy individual with an infected person. Excessive heat, high relative humidity and usage of tightly fitting clothes as well as synthetic garments have high correlations to more severe and frequent disease [7].

Case 1

A 38 years old female patient with fair complexion having complaint of ring worm on left side of cheek with intolerable itching and burning sensation since 1 year. Complaint aggravate by warmth of bed. She also complaints of white discharge per vaginum, profuse acrid with offensive smell since six months, amelioration by washing it by cold water. She has pain in her lower extremities.

Past history

Typhoid at the age of 12 year treated With Allopathic treatment.

Family history

Father- Diabetes mellitus
 Mother - Hypertension
 Younger brother- Bronchial Asthma

Gynaecological History-

Menarche- at the age of 14 years
 LMP- 02/12/2022
 Menses- on time
 Any Discharge- White discharge per vaginum
 Quantity-profuse
 Nature-Acid
 Offensive smell

Physical generals:-

Appetite- 5 chapatis/ meal, increased
 Thirst- Thirsty(of cold water at short interval)
 Sleep- Sleeplessness (Due to persistent thoughts)
 Desire- ice cream
 Stool- constipation goes for motion with the interval of 2-3 days, dry hard stool
 Dreams of snakes
 Dreams of death of family members

Mental generals

She was very suspicious by her nature, she asked doctor can you please prescribe the medicine, I will buy it from my self, she have no trust on doctor also about the quality of medicine. Constant fear of death, she said that, it seems my disease is now become incurable. Loquacity, continuously talking while narrating her complaints .Always want clean home according to her, never love the work done by others, easily got offended on slightest matter.

Totality of symptoms after analysis and evaluation-

1. Ring worm on left side of cheek, intolerable itching with burning.
2. Aggravation by warmth of bed
3. Amelioration by cold water
4. Leucorrhoea, profuse, acrid with offensive smell
5. Pain in Lower extremities
6. Appetite- Increased

7. Thirst -for cold water in short interval
8. Desire- For ice cream
9. Constipation, goes for motion after 2-3 days, dry hard stool
10. Dreams of snakes
11. Dreams of death of relatives
12. Sleeplessness
13. Suspicious by nature
14. Easily offended
15. Fear of death due to incurable disease
16. Fastidious
17. Loquacity

Conversion of Rubrics

Table 1: Conversion of symptom into rubrics

S.no	Symptoms	Rubric
1	Ring worm on left side of cheek	eruption- ring worm
2	intolerable itching	itching -intolerable
3	Burning sensation	burning
4	< bed warmth	itching bed aggravation
5	Leucorrhoea acrid	Female genitalia- Leucorrhoea acrid
6	Leucorrhoea offensive smell	leucorrhoea offensive
7	Pain in Lowe extremities	Extremities-pain-lower
8	Appetite- Increased	appetite-Increased
9	Thirst for cold water with short interval	thirst for cold water
10	Desire for ice cream	General food and drink
11	Constipation	Constipation
12	Dreams of snakes	Dreams of snakes
13	Dreams of death of close relative	Dreams dead of relatives
14	Sleeplessness	Sleeplessness
15	Suspicious by nature	Suspicious
16	Easily offended	Offended easily
17	Fastidious	Fastidious
18	Loquacity	Loquacity
19	Fear of death, she thinks that her disease is now incurable	Fear -death

Repertorial Sheet

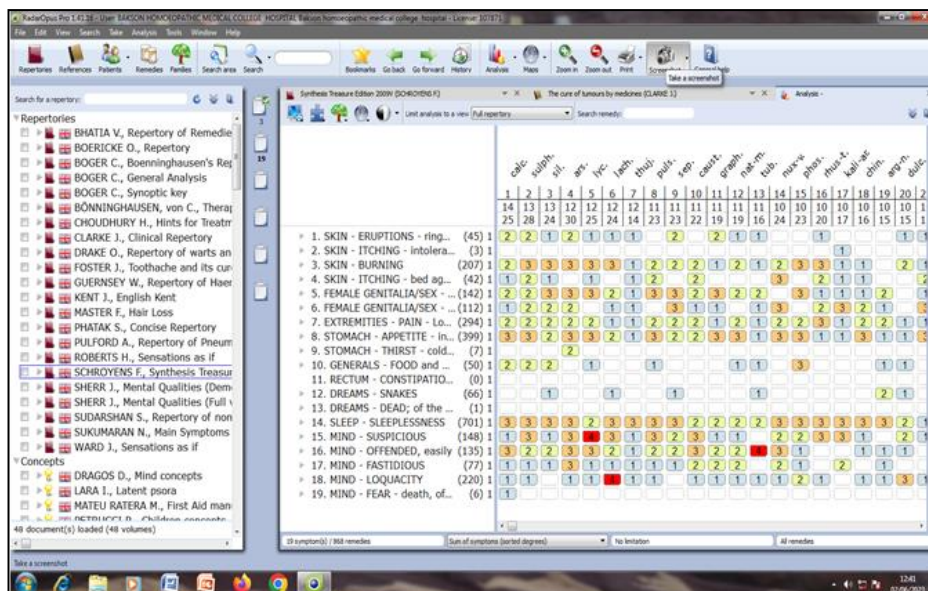


Fig 1: Repertorial Sheet

Repertorial Result ^[8]

1. Calcarea carbonica- 25/14
2. Sulphur-28/13
3. Silicea-24/13
4. Arsenic album-30/12
5. Lycopodium-25/12

Prescription

After Consulting Materia medica ^[9], Calcarea carbonica 200c one dose orally given to the patient, followed by placebo for 7 days on 25/12/2022

Follow ups

Table 2: Follow –up Sheet

S. No	Date	Symptoms	Prescription
1	02/01/2023	Itching -slight better Lesion were same as before Intense burning is their No relief in sleeplessness Leucorrhoea-slight better Appetite- same as before Pain in lower extremities- same as it is Constipation-slight better	Placebo 200 /TDS /for 7 days
2	11/01/2023	Itching-increased Lesions stats reducing Burning sensation- slight better Leucorrhoea- better Pain in lower extremities- slight better Sleep is now improving Stool is still dry but now goes for motion on daily bases	Placebo 200 /TDS /for 7 days
3	18/01/2023	Itching mainly when she worked there in kitchen Lesions on face better Burning- present Leucorrhoea- better Pain in lower extremities- better Constipation- better Sleep- better	Placebo 200 /TDS /for 7 days
4	28/01/2023	Itching - better Lesion started to dry up No new lesions appeared Burning sensation- better now Pain in lower extremities- again started Constipation- better now	Placebo 200 /TDS /for 7 days
5	9/02/2023	All general complaints are better now No burning Slight itching Leucorrhoea - better Pain in lower extremities- better now	Placebo 200 /TDS /for 15 days
6	26/02/2023	Lesion on face completely dry No itching No burning Leucorrhoea better now Pain in lower extremities - better	Placebo 200 /TDS /for 15 days
7	12/03/2023	All complaints are better now	Placebo 200 /TDS /for I month

Result

The skin lesions on face with intolerable itching and burning sensation with other symptoms like leucorrhoea and pain in

lower extremities and constipation showed improvement by Sulphur 200c. Ring worm completely disappeared within a period of 2.5 months of constitutional Homoeopathic treatment.

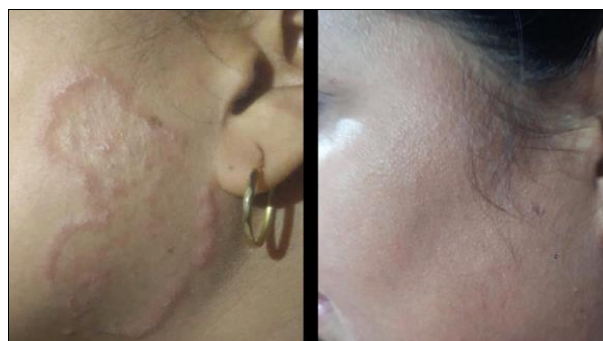

Fig 2: Before Treatment

Fig 3: After Treatment

Case 2

A 10 year old boy visited to clinic with complaint of ring worm on right side of face with itching & dryness with stinging type of pain since three months.

Past history: He was a preterm baby, weight 1500 gm, delivered at 32 weeks, admitted in NICU for 20 days on C-PAP oxygen support
-Recurrent cold and cough took Allopathic treatment

Family history

Father- Hypertension
Mother - Thyroid

Physical generals

Appetite-increased
Thirst- Thirsty, unquenchable
Aversion- onions
Desire- warm drinks, like tea, coffee, warm milk, soup
Stool- watery stool every time
Thermal - chilly

Mental generals

His mother told that, he never stay alone in house, she also told that she don't know the reason but due to fear he never go out side. Afraid of road side accident. He got easily aggravated when someone from her family wants to console him for his mistake.

Totality of symptoms after analysis and evaluation-

1. Ring worm on right side of cheek, stinging type of pain with itching.

2. Appetite- Increased
3. Thirst - unquenchable
4. Aversion- onions
5. Desire-Warm drinks
6. Stool- watery
7. Thermal - chilly
8. Fear of being alone, never stay alone at house
9. fear of road side accidents
10. Consolation aggravation

Conversion of Rubrics

Table 3: Conversion of symptom into rubrics

S.no	Symptoms	Rubric
1	Ring worm on right side of cheek	Ring worm
2	Stinging type of pain	Pain-stinging
3	Itching	Skin-Itching
4	Appetite-increased	Appetite-Increased
5	Thirst-unquenchable	Unquenchable thirst
6	Aversion-onions	General food and drink aversion-onion
7	Desire-warm drinks	General food and drink – desire worm drink
8	Stool- watery	Stool watery
9	Thermal-Chilly	Generals-Chilly person
10	Fear of being alone, never stay alone at house	Fear -alone
11	Fear of road side accidents	Fear of accidents
12	Consolation aggravation	Consolation agg

Repertorial sheet

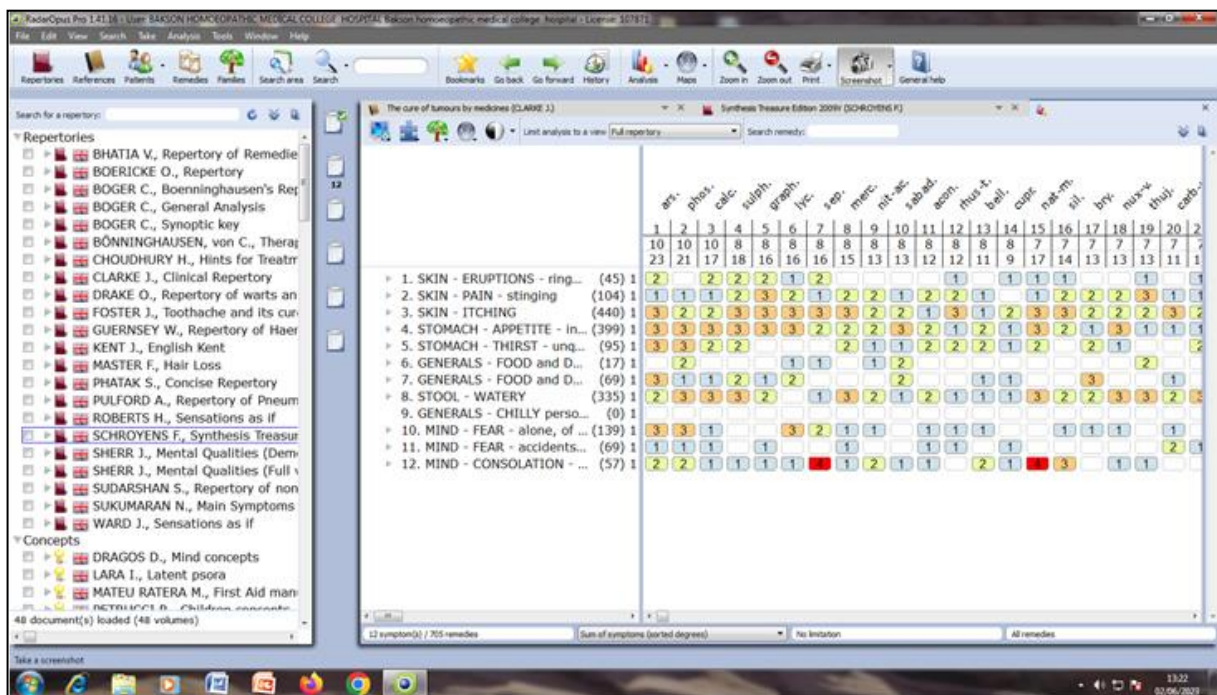


Fig 4: Repertorial sheet

Repertorial Result-viii

1. Arsenic album-23/10
2. Phosphorus-21/10
3. Calcara carbonica-17/10
4. Sulphur-18/8
5. Graphites-16/8

Prescription

After consulting material medica ix, Arsenic album 200 1 dose orally followed by placebo for 10 days on 22/03/2023

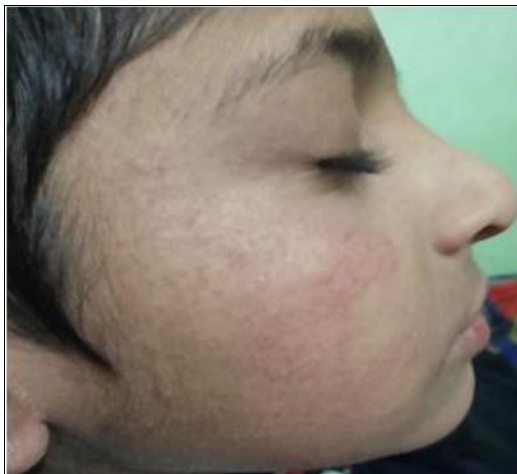Follow-ups

Table 4: Follow-up sheet

S. No	Date	Symptoms	Prescription
1	02/04/2023	Itching -improved Lesion - no changes Stool-hard	Placebo 200 /TDS /for 7 days
2	10/04/2023	Itching-off and on Lesions stats reducing from lower side of face Stool-semisolid	Placebo 200 /TDS /for 7 days
3	18/04/2023	Itching-only in night now Lesins -reducing Stool- again watery	Placebo 200 /TDS /for 7 days
4	25/04/2023	Itching - better Lesion started to dry up No new lesions appeared Pain is better now Stool- satisfactory,semisolid stool	Placebo 200 /TDS /for 7 days
5	4/05/2023	All general complaints are better now Slight- itching Pain- better Lesion-completely gone	Placebo 200 /TDS /for 7 days
6	12/05/2023	Pain and itching better Ring worm lesion completely cured Stool-semi solid	Placebo 200 /TDS /for 7 days

Result

The skin lesions on right side of face with itching and other symptoms like watery stool showed improvement by *Arsenic album 200c*. Ring worm completely disappeared within a period of 1.3 months of constitutional Homoeopathic treatment.

**Fig 5:** (Before Treatment)**Fig 6:** (After treatment)**Case 3**

A 4 year old boy visited to clinic on 02/02/2023 with complaint of ring worm on both cheeks, with marked burning sensation, intense itching, scratch until it bleeds. Amelioration by scratching. Grinding of teeth especially at night. Saliva falls down from mouth during sleep. He also complaint of pain in abdomen off and on.

Past history

Recurrent coryza took Allopathic treatment

Family history

Father- Migraine

Mother - Diabetes

Physical generals

Appetite-Ravenous Hunger

Thirst- Decreased

Desire- Undigestable things (chalk, mud)

Stool- Hard, dry

Mental generals

His mother shared an incident last year her husband loudly shout on her in front of both kids, although he was 3 years old at that time but he still remembered that incident, hatred feeling for his father with marked irritability.

Totality of symptoms after analysis and evaluation

1. Ring worm on both cheeks, with marked burning sensation.
2. Intense itching, scratch until it bleeds.
3. Amelioration by scratching.
4. Grinding of teeth specially at night.
5. Saliva falls down from mouth during sleep.
6. Appetite- Ravenous hunger
7. Desire- Undigestable things (chalk, mud)
8. Thirst – decreased
9. Pain in abdomen on and off.
10. Stool- Hard, dry
11. Marked irritability
12. Hatred feeling for his father

Conversion of symptoms into rubrics

Table 5: Conversion of symptoms into rubric

S.no	Symptoms	Rubric
1	Ringworm on both cheeks	Eruption -ring worm
2	Marked burning sensation	Skin-burning
3	Intense itching, scratch until it bleeds.	Itching scratching- agg- bleeds, must scratch until it
4	Amelioration by scratching.	Itching scratching-amel
5	Grinding of teeth specially at night.	Teeth grinding-sleep-during-agg
6	Saliva falls down from mouth during sleep.	Salivation-sleep-during-agg
7	Appetite-Ravenous Hunger	Appetite- ravenous
8	Desire- indigestible things (chalk, mud)	food and drink, indigestible things-desire
9	Thirst-Decreased	Thirst decreased
10	Pain in abdomen on and off	Abdomen pain
11	Stool- Hard	Stool-hard
12	Stool-dry	Stool-dry
13	Marked irritability	Mind-irritability
14	Hatred feeling for his father	Mind-Hatred

Repertorial sheet

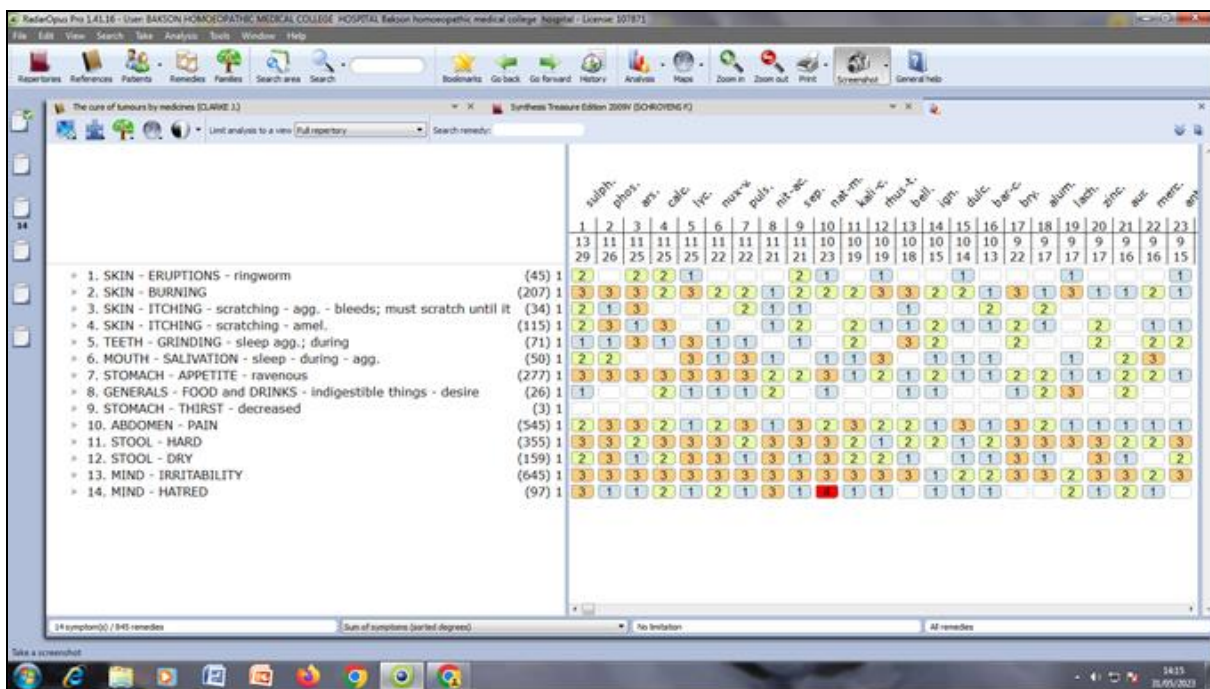


Fig 7: Repertorial Sheet)

Repertorial Result-viii

- 1- Sulphur-29/13
- 2- Phosphorus-26/11
- 3- Arsenic album-25/11
- 4- Calcara carbonica-25/11
- 5- Nux vomica- 25/11

Prescription

After Consulting Materia medica ix,Sulphur 200c one dose orally given to the patient, followed by placebo on 22/01/2023 for 15 days.

Follow-up

Table 6: Follow-up sheet

S.no	Date	Symptom	Prescription
1	10/02/2023	Itching -better Lesion were same as before Bleeding on scratching still present	Placebo 200/TDS /for 7 days
2	18/02/2023	Lesion start reducing All general complaints are better now Stool- still dry and hard	Placebo 200/TDS /for 7 days
3	27/02/2023	Lesions and burning - better Itching- slightly increased Stool- better	Placebo 200/TDS /for 7 days
4	8/03/2023	No new lesion appear	Placebo 200/TDS /for 7 days

		Itching better Bleeding - better Burning- better	
5	22/03/2023	Over all symptoms are better now No itching No burning	Placebo 200/TDS /for 1month
6	24/04/2023	Lesions completely cured No burning No itching Stool-semisolid All general complaints are better now	Placebo 200/TDS /for 15 days

Result

The skin lesions on both side of face with itching and burning, grinding of teeth with salivation and other symptoms like dry hard stool,pain in abdomen showed improvement by *Sulphur 200 c*. Ring worm completely disappeared within a period of 3 months of constitutional Homoeopathic treatment.

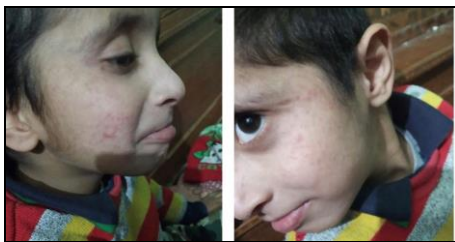

Fig 8: Before Treatment



Fig 9: After Treatment

Discussion

This case series describes the importance of single individualized constitutional homoeopathic treatment in obstinate condition called Tinea faciei. The task of treating ringworm by conventional oral medicine, external application was unsatisfactory. After entire failure patients choose homoeopathic treatment to get permanent cure. The remedies *calcareo carbonica 200c*, *Arsenic album 200c*, *Sulphur 200c* was selected after proper repertorization of case, eruptions over face completely cured after homoeopathic treatment with regular follow -ups.

Conclusion

A complete disappearing of skin eruptions with complaints without any recurrence with photographic evidence. Homeopathic medicines help control fungal growth, reduce the inflammation, redness and itching and help restore normal healthy skin. They also prevent future recurrences of the condition. These cases showed positive role of homoeopathy in treating the pathology of Tinea faciei.

Consent of Patient

All patients has agreed that their imagesand other clinical information is to be reported in the journal. The patient understood her name and initials will not be included in the manuscript and due efforts will be taken to conceal her identity.

Conflict of interest: None

Acknowledgement

Deeply acknowledge the all patients for allowing us to collect the data.

References

- Hsu S, Le EH, Khoshevis MR. Differential diagnosis of annular lesions. Am Fam Physician. 2001;64(2):289-296. [PubMed] [Google Scholar]
- Lin RL, Szepietowski JC, Schwartz RA. Tinea faciei: an often deceptive facial eruption. Int J Dermatol. 2004;43:437-40
- Romano C, Ghilardi A, Massai L. Eighty-four consecutive cases of tinea faciei in Siena, a retrospective study (1989-2003). Mycoses. 2005;48:343-346.
- Jorquera E, Moreno JC, Camacho F. Tinea faciei: epidemiology. Ann Dermatol Venereol. 1992;119:101-104.
- Leung AKC. Tinea corporis. In: Leung AKC, ed. Common Problems in Ambulatory Pediatrics: Specific Clinical Problems, volume 2. New York: Nova Science Publishers, Inc.; c2011. p. 19-22.
- Lynn C. Garfunkel, Jeffrey M. Kaczorowski and Cynthia Christy, Pediatric Clinical Advisor Instant Diagnosis and Treatment, Second Edition • 2007, ISBN978-0-323-03506-
- Marks R, Motley R. Roxburgh's common skin diseases. 18th edition. Boca Raton: CRC Press. 2015. p. 40-44.
- Software. RADAR OPUS PRO1.41.16 version
- <http://www.homeoint.org/books/boericmm/l/lyc.htm>

How to Cite This Article

Neha N, Ravi KP, Ajay K, Kanak S. Usefulness of Homeopathic treatment in Tinea faciei: A case series. International Journal of Homoeopathic Sciences. 2023;7(2):492-498.

Creative Commons (CC) License

This is an open access journal, and articles are distributed under the terms of the Creative Commons Attribution-NonCommercial-ShareAlike 4.0 International (CC BY-NC-SA 4.0) License, which allows others to remix, tweak, and build upon the work non-commercially, as long as appropriate credit is given and the new creations are licensed under the identical terms.