

A case report of prurigo nodularis responsive to Homoeopathy

Nidhi Mahajan^{1*}, Deeksha Chaturvedi², Anita Alaria³, Girendra Pal^{1,4}

¹Central Research Institute of Homoeopathy, ³Department of Forensic Medicine and Toxicology, Swasthya Kalyan Homoeopathic Medical College and Research Centre, ⁴Homoeopathy University, Jaipur, Rajasthan, ²Department of Forensic Medicine and Toxicology, Bakson Homeopathic Medical College and Hospital, Greater Noida, Uttar Pradesh, India

Abstract

Introduction: Prurigo nodularis (PN) is a chronic, benign neurodermatitis. The exact cause is unknown. In majority, cases of PN do not have a complete resolution of the nodules even with treatment. **Case Summary:** Here, a diagnosed case of PN of an 18 year old female with a history of 1 year old eczematous lesion is presented. On the basis of the totality of symptoms, homoeopathic medicine *Natrium muriaticum* was prescribed and gradually the patient showed stable improvement in the domain of signs and symptoms and reached remission by the end of 4 months. There was no recurrence over the next 1 year. This case report evidently suggests that Homoeopathy can serve as a possible treatment option for the management of PN cases.

Keywords: Case report, Homoeopathy, *Natrium muriaticum*, Prurigo nodularis

INTRODUCTION

‘Pruritus’ is originally derived from the Latin word ‘prurire’ -means ‘itch’,^[1] the medical term for itching. ‘Prurigo’ is a related term that describes the changes appear in the skin after it has itched and been scratched for a long time. In prurigo nodularis (PN), these changes take the form of firm very itchy bumps or nodules on the skin’s surface. Lesions can resolve when the person stops scratching the area, although in most of the cases, this can be very difficult without proper treatment.^[2]

PN clinically presents with hard, crusty, intensely itchy lumps, in which itching is so intense that people scratch themselves to the point of bleeding. Painful hard lumps range from very small to about a half inch across and have a rough and dry top; there may be a few or hundreds. Common sites of involvement are outer parts of the arms, shoulders and legs. The trunk, face and even palms can also get affected.^[3]

The pathophysiology of PN remains to be fully elucidated yet; emerging evidence suggests a principal role of neuroimmune alteration in the pathogenesis of PN.^[4] In some cases, it can be seen with other comorbidities such as atopic dermatitis (eczema), lymphoma, chronic autoimmune cholestatic hepatitis, HIV infection, severe anaemia or a chronic kidney disease-related itching known as uremic pruritus.^[3]

Differential diagnosis of PN on the basis of clinical presentation and skin biopsy includes dermatitis/eczema, dermatomyositis, pemphigus, hypertrophic lichen planus, nodular scabies, dermatofibromas and keratoacanthomas.^[5]

PN is a clinical diagnosis, biopsies are often required to confirm the cases that do not respond to first-line therapies or those with secondary complications such as bleeding or ulceration and other suggested laboratory investigations include a complete blood cell count, complete metabolic panel, thyroid, liver and kidney function tests, hepatitis B and C serologies and HIV serology to exclude association as comorbid condition.^[4]

It is an understudied disease compared to other inflammatory skin diseases. There is no standardised diagnostic evaluation criteria or treatment regimen for the disease. The highly pruritic, chronic nature and psychological burden (disease-associated anxiety and depression) of this disease suggests need for greater recognition of PN and an evidence-based workup is necessary for optimal patient management.^[4] Conventional treatment includes use of topical or intralesional steroids,

***Address for correspondence:** Dr. Nidhi Mahajan,
Central Research Institute of Homoeopathy,
Sector 26, Pratap Nagar, Jaipur - 302 033, Rajasthan, India.

Received: 12.05.2019; **Accepted:** 20.02.2020; **Published:** 09.04.2020.

Access this article online

Quick Response Code:



Website:
www.ijrh.org

DOI:
10.4103/ijrh.ijrh_37_19

This is an open access journal, and articles are distributed under the terms of the Creative Commons Attribution-NonCommercial-ShareAlike 4.0 License, which allows others to remix, tweak, and build upon the work non-commercially, as long as appropriate credit is given and the new creations are licensed under the identical terms.

For reprints contact: reprints@medknow.com

How to cite this article: Mahajan N, Chaturvedi D, Alaria A, Pal G. A case report of prurigo nodularis responsive to Homoeopathy. *Indian J Res Homoeopathy* 2020;14:64-9.

severe or recalcitrant cases necessitates use of phototherapy or systemic immunosuppressives. Thalidomide, lenalidomide, opioid receptor antagonists and NK1r antagonists with their toxicity profile makes them less favourable.^[6] In majority of cases, PN do not have a complete resolution of the nodules with conventional treatment.^[7]

Literature review revealed a case report of 63-year-old male patient treated with *Lycopodium Clavatum* 200, 1M and 10M with *Natrium sulphuricum* 6X within 6 months and with added follow-up of 3 months with no relapse.^[5] Given the chronic and highly pruritic nature of the disease, there is a very high burden of disease, including high rates of associated psychological effects on the patients as anxiety and depression among the patients of PN.^[4] Homoeopathy as a holistic approach in this case report suggests an effective treatment measure for PN.

CASE REPORT

A diagnosed case of PN, of an 18-year-old Hindu female student, visited the OPD (on 01 August, 2017) of CCRH Collaborative OPD at Dr. M. P. K. Homoeopathic Medical College and Hospital, Jaipur, India, with complaints of multiple painful nodular lesions with itching over bilateral legs, forearms and back [Figures 1a, 2a, 3a and 4a] for 1 year. The lesions exuded discharge on scratching, discharge was sticky, watery and bloody on continuous scratching and itching aggravated at night and on scratching. The patient was apparently well 1 year back when gradually she started developing complaint of itching followed by painful nodular lesions. The patient took allopathic medicines for the same with temporary relief for 9 months but lesions relapsed.

There was a history of measles in 2007. She was not on any on-going allopathic medicine or other alternative medicines.

In family history, her mother had hypertension.

She enjoyed dancing (joined dance school for learning) and was passionate for it.

Menstrual cycle was regular (28–30 days), moderate flow and lasting for 3–4 days. There were no associated symptoms. On examination of the skin, there were multiple blackish, blue bumps (nodules) over the forearms, back and legs with firm consistency and sticky, watery, bloody discharge on scratching.

Self-rating, patient global assessment score (PGA, rating was scored on 0–10 scale, 'considering all the ways in which illness affects the patient', minimum and maximum scores indicates 0-very good and 10-very bad) was 6 on the first visit.

There was no significant finding in general and other systemic examinations.

HOMOEOPATHIC GENERALS

Mental generals

One year back, the patient had issues with her father on her love relationship with a boy. Her father scolded badly and forced her to stay away from the relationship as it was distracting

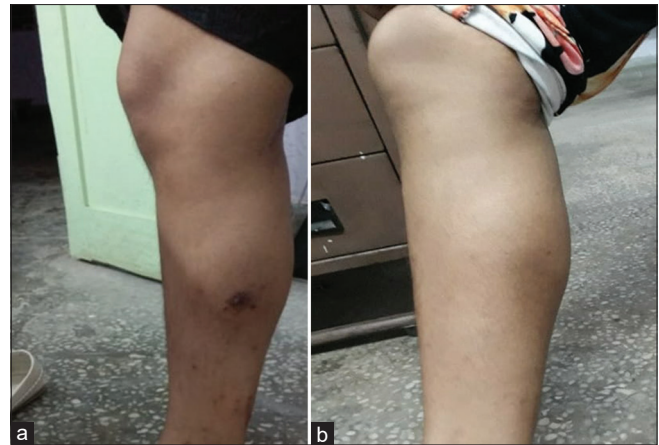


Figure 1: (a) Pre-treatment right leg, (b) post-treatment right leg

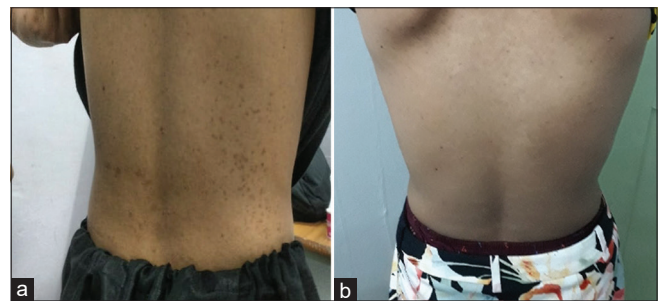


Figure 2: (a) Pre-treatment back, (b) post-treatment back

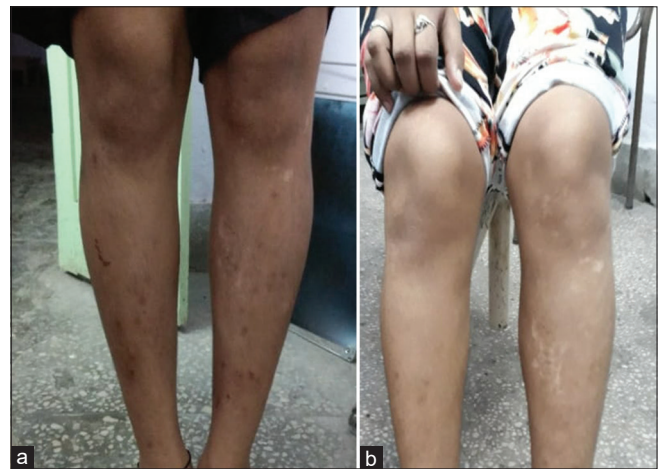


Figure 3: (a) Pre-treatment b/l leg, (b) post-treatment b/l leg

her from studies. The incidence affected the patient badly⁺⁺⁺, and she lost her focus on studies and failed in a subject twice leading to further disappointment. The significance of this event as mentioned is that it has been taken as ailment from disappointment as all her complaints had started after that incident. At last, she changed the stream and focused herself on her passion, dancing and decided it as carrier option. She could not bear rude behaviour, which makes her cry⁺⁺.

Physical generals

The physical generalities were thirst for small quantities⁺⁺

Table 1: Timeline including follow-up

Date	Signs and symptoms	Prescription Medicine with potency and dose
14 August 2017	Itching in lesions was reduced. Pain, consistency of the lesions and discharges (sticky, watery and bloody) from the lesions on forearms, back and legs were same. Sleep-no episodes of somnambulism	<i>Nat. mur.</i> 200/1 dose <i>Placebo</i> 30/tds/14 days
29 September 2017	Itching and discharges (sticky, watery) from lesions reduced. Pain, consistency of the lesions on forearms, back and legs were same. Sleep-no episodes of somnambulism	<i>Placebo</i> 30/tds/14 days
16 October 2017	Patient didn't report in between and had taken Allopathic medicines (Calpol 650 mg, Azee 500, Pandom-D, A to Z tablets) for viral fever Few new papular, itching lesions appeared on the shoulder and neck Itching, pain, consistency of the lesions and discharge (watery) from the lesions on forearms, back and legs were same. Sleep-no episodes of somnambulism	<i>Nat. mur.</i> 200/1 dose <i>Placebo</i> 30/tds/14 days
14 October 2017	No new lesion appeared Lesions on the shoulder and neck were relieved. Itching, pain in lesions were markedly reduced and occasional discharges (watery) from lesions. Consistency of the lesions on forearms, back and legs were same Sleep-one episode of somnambulism	<i>Placebo</i> 30/tds/14 days
30 November 2017	No new lesions appeared Discharges (watery) from the lesions of legs on scratching increased. Itching, pain, consistency of the lesions and discharges from the lesions on forearms, back were same. Sleep- no episode of somnambulism	<i>Nat. mur.</i> 1M/1 dose <i>Placebo</i> 30/tds/14 days
4 December 2017-8 June 2018	No new lesions, no discharge, no itching, no new complaints [Figures 1b, 2b, 3b and 4b]. Sleep-one episode of somnambulism	<i>Placebo</i> 30/tds/14 days

(takes sips) and aversion to sweets⁺⁺. She often walks during sleep, she never realises that she walks and since childhood, she is suffering with the complaint (episodic-once or twice in a month) and had taken no treatment for the same.

Analysis of the case

After analysis and evaluation, the characteristic symptoms were considered for framing the totality. Ailments from disappointment, passionate, sensitive to rudeness and somnambulism were important mental symptoms in this case. Thirst for small quantities and aversion to sweets were physical generals. Itching aggravated at night; there were multiple itching, painful, nodular lesions on the forearms, back and legs and discharge was watery, sticky and bloody on scratching lesions. Miasmatic evaluation for the presenting symptom was done with the help of 'Chronic disease by Dr. Samuel Hahnemann,' which showed the predominance of psoric miasm.

Selection of remedy was based on repertorisation of the case using Synthesis Repertory, version 9.0 of RADAR software. The repertorisation chart is shown in Figure 5.

On the basis of reportorial analysis and after consulting *Materia Medica*,^[8] *Natrium muriaticum* was selected and 200 potency in single dose was prescribed followed by placebo for 14 days on the first visit (01 August, 2017) [Table 1].

DISCUSSION

The above case report shows that homoeopathic medicines are helpful in the treatment of PN. In this case, *Natrium muriaticum* in 200C and 1M potencies was prescribed, which covered the totality of symptoms of the patient and it has

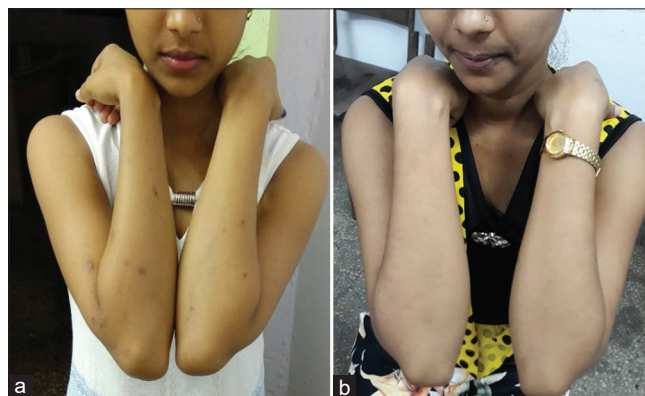

Figure 4: (a) Pre-treatment forearms, (b) post-treatment forearms

shown positive results. Somnambulism was considered as an accessory symptom in the case, gradually the episodes of somnambulism were reduced and presently there is absolute absence of such episodes.

Improvement status of the patient was assessed on the basis of self-rating scale i.e., patient global assessment score with pre-treatment score being 6 which was reduced to 0 post-treatment.

In this case, the total score of outcome as per Modified Naranjo Criteria was 8, which was close to the maximum score of 13. This explicitly shows the causal attribution of the single medicine homoeopathic treatment *Natrium muriaticum* towards remission of the PN in this case [Table 2].

The general approach in Homoeopathy towards treatment is 'The real sick man is prior to the sick body.'^[9] In this case, important mental generals, physical generals and particulars, i.e., ailments from disappointment, passionate, sensitive to

Table 2: Assessment by Modified Naranjo Criteria score

	Yes	No	Not sure or N/A
1. Was there an improvement in the main symptom or condition for which the homoeopathic medicine was prescribed?	+2		
2. Did the clinical improvement occur within a plausible time frame relative to the drug intake?	+1		
3. Was there an initial aggravation of symptoms? (need to define in glossary)		0	
4. Did the effect encompass more than the main symptom or condition, i.e., were other symptoms ultimately improved or changed?	+1		
5. Did overall wellbeing improve? (suggest using validated scale)	+1		
6. A) Direction of cure: did some symptoms improve in the opposite order of the development of symptoms of the disease?			0
6. B) Direction of cure: Did at least two of the following aspects apply to the order of improvement of symptoms From organs of more important to those of less importance From deeper to more superficial aspects of the individual From the top downwards			0
7. Did "old symptoms" (defined as non-seasonal and non-cyclical symptoms that were previously thought to have resolved) reappear temporarily during the course of improvement?		0	
8. Are there alternate causes (other than the medicine) That with a high probability could have caused the improvement? (consider known course of disease, other forms of treatment, and other clinically relevant interventions)		+1	
9. Was the health improvement confirmed by any objective evidence? (e.g., lab test, clinical observation, etc.)	+2		
10. Did repeat dosing, if conducted, create similar clinical improvement?		0	
	Total score-8		

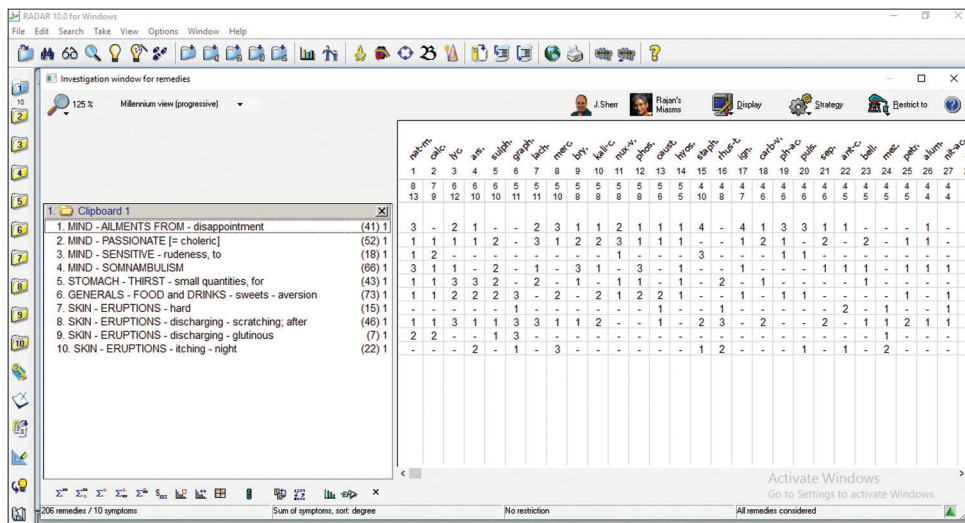


Figure 5: Repetorisation chart

rudeness and somnambulism, were important, thirst for small quantities, aversion to sweets, itching aggravation at night, itching, painful, nodular lesions on forearms, back, and legs, discharges-watery, sticky were included for repertorisation purpose.

There is no specific conventional treatment for PN and available treatment includes oral antihistamines and steroids that may be applied to the skin (topical) or taken internally (systemic). A combination of several treatments may need to be tried but they may not offer complete relief from symptoms for some.^[10-13]

There is no definite diagnostic criteria and treatment regimen for PN so such cases are generally poorly managed. Individualised medicine helps the body to heal itself and hence can serve as a possible treatment option for PN. However, a

prospective research study is suggested for scientific validation as this is a single case report.

CONCLUSION

The present case report shows the role of Homoeopathy in treating the cases of PN where *Natrium muriaticum* was prescribed as an individualised medicine and showed evident positive results. The outcome of this case report will improve the knowledge of the clinicians in suggesting proper patient management, which will benefit the patients suffering from PN.

Declaration of patient consent

The authors certify that they have obtained patient consent via E-mail and the patient has given her consent for her photographs and other clinical information to be reported in the journal. The patient was made to understand that her name

and initials will not be published and due efforts will be made to conceal her identity.

Acknowledgement

The authors acknowledge Dr. Chaturbhujaya Nayak, President, Homoeopathy University, Jaipur, for his encouragement and guidance regarding case report writing and scientific publication. The authors also acknowledge Dr. Atul Kumar Singh, Principal, Dr. M.P.K., Homoeopathic Medical College, Hospital and Research Centre, for guidance and support.

Financial support and sponsorship

Nil.

Conflicts of interest

None declared.

REFERENCES

1. Dictionary by Merriam-Webster: America's Most-Trusted Online Dictionary; 2019. Available from: <https://www.merriam-webster.com/>. [Last accessed on 2018 Jun 27].
2. British Association of Dermatologists; 2018. p. 2-3. Available from: <http://www.bad.org.uk/>. [Last accessed on 2018 Sep 25].
3. Savill T, Warner E. Savill's System of Clinical Medicine. 14th ed. London: Edward Arnold; 2005;951.
4. Kwon CD, Khanna R, Williams KA, Kwatra MM, Kwatra SG. Diagnostic Workup and Evaluation of Patients with Prurigo Nodularis. *Medicines (Basel)* 2019;6.
5. Khatri J. Homoeopathy in Prurigo Nodularis; 2018. Available from: <https://hpathy.com/clinical-cases/homoeopathy-in-prurigo-nodularis/>. [Last accessed on 2019 Oct 10].
6. Kowalski EH, Kneiber D, Valdebran M, Patel U, Amber KT. Treatment-resistant prurigo nodularis: Challenges and solutions. *Clin Cosmet Investig Dermatol* 2019;12:163-72.
7. Prurigo nodularis. Genetic and Rare Diseases Information Center. U.S. Department of Health and Human Services; 2018. Available from: <https://rarediseases.info.nih.gov/diseases/7480/prurigonodularis>. [Last accessed on 2018 Sep 25].
8. Clarke JH. A Dictionary of Practical Materia Medica. New Delhi: B. Jain Publishers; 1999. p. 549-62.
9. Kent JT. Lectures on Homoeopathic Philosophy. 5th ed. New Delhi: B Jain Publishers (P) Ltd.; 1989. p. 766-72.
10. Oakley A. Nodular Prurigo. *Dermnetz*; September, 2014. Available from: <https://www.dermnetz.org/topics/nodularprurigo/>. [Last accessed on 2018 Sep 25].
11. Prak AH, De la Rosa KM. Prurigo Nodularis. *Medscape Reference*; 05 June, 2017. Available from: <https://emedicine.medscape.com/article/1088032overview>. [Last accessed on 2018 Sep 25].
12. Watsky K. Prurigo Nodularis. *UpToDate*; 8 March, 2018. Available from: <https://www.uptodate.com/contents/prurigonodularis>. [Last accessed on 2018 Sep 25].
13. OssorioGarcía L, JiménezGallo D, RodríguezMateos ME, ArjonaAguilera C, LinaresBarrios M. Treatment of prurigo nodularis with lenalidomide. *Dermatol Ther* 2017;30. doi: 10.1111/dth.12451.

होम्योपैथी के प्रति संवेदनशील प्रुरिगो नोड्युलेरिस मामले का विवरण

परिचय: प्रुरिगो नोड्युलेरिस एक पुरानी, सौम्य न्यूरोडर्मेटाइटिस है। सटीक कारण अज्ञात है। ज्यादातर, प्रुरिगो नोड्युलेरिस (पीएन) के मामलों में उपचार के द्वारा भी नोड्युलेरिस का पूर्ण समाधान नहीं होता है। **मामले का सारांश :** प्रुरिगो नोड्युलेरिस से ग्रसित एक 18 साल की महिला एक्जिमाटस त्वचा के घाव के एक साल के इतिहास के साथ उपचार के लिये आई। लक्षणों की समग्रता के आधार पर, होम्योपैथिक दवा *नैट्रियम म्यूरिएटिकम* निर्धारण किया गया और धीरे-धीरे रोगी ने संकेतों और लक्षणों में स्थिर सुधार दिखाया और 4 महीने के भीतर स्वस्थ होने के कगार पर पहुंच गया। अगले एक साल तक कोई पुनरावृत्ति नहीं हुई। इस मामले का विवरण स्पष्ट रूप से बताता है कि होम्योपैथी प्रुरिगो नोड्युलेरिस के मामलों के प्रबंधन के लिए एक संभावित उपचार विकल्प के रूप में काम कर सकती है।

Un rapport de cas de prurigo nodulaire réactive à l'homéopathie

INTRODUCTION: Le prurigo nodulaire est une névrodermite chronique bénigne. La cause exacte est inconnue. En majorité des cas de prurigo nodulaire (PN) n'ont pas une résolution complète des nodules même avec un traitement. **RÉSUMÉ DU CAS:** Ici, un cas diagnostiqué de prurigo nodulaire d'une femme de 18 ans présentait des antécédents de lésion cutanée eczémateuse depuis un an. Sur la base de la totalité des symptômes, un médicament homéopathique *Natrium muriaticum* a été prescrit et le patient a progressivement montré une amélioration stable dans le domaine des signes et symptômes et a atteint une rémission au bout de 4 mois. Il n'y a pas eu de réapparition au cours de l'année suivante. Ce rapport de cas suggère évidemment que l'homéopathie peut servir comme une option de traitement possible pour la gestion des cas de prurigo nodularis.

Informe de un caso de prurigo nodular que responde al tratamiento homeopático

Introducción: El prurigo nodular es una neurodermatitis benigna crónica. La causa exacta es desconocida. En su mayoría, los casos de prurigo nodular (PN) no muestran una resolución de los nódulos ni siquiera con tratamiento.

Resumen del caso: Se presenta un caso diagnosticado de prurigo nodular de una mujer de 18 años con un año de historia de lesiones cutáneas eczematosas. Sobre la base de la totalidad de los síntomas, se prescribió medicina homeopática *Natriummuriaticum*. Gradualmente, la paciente fue mostrando una mejoría estable en el dominio de los signos y síntomas y llegó a una remisión al final de los 4 meses. No se produjeron recurrencias a lo largo del siguiente año. Este informe de caso clínico indica claramente que la homeopatía puede servir como posible opción terapéutica para el manejo de los casos de prurigo nodular.

Ein Fallbericht über Prurigo nodularis, der auf Homöopathie anspricht

EINLEITUNG: Prurigo nodularis ist eine chronische, gutartige Neurodermitis. Die genaue Ursache ist nicht bekannt. In der Mehrzahl der Fälle von Prurigo nodularis (PN) kommt es auch unter Behandlung nicht zu einer vollständigen Auflösung der Knoten. **FALLZUSAMMENFASSUNG:** Hier ein diagnostizierter Fall von Prurigo nodularis bei einer 18-jährigen Frau mit einer einjährigen Vorgeschichte einer ekzematösen Hautläsion. Auf der Grundlage der Gesamtheit der Symptome wurde das homöopathische Medikament *Natrium muriaticum* verschrieben, und die Patientin zeigte nach und nach eine stabile Verbesserung im Bereich der Anzeichen und Symptome und erreichte nach 4 Monaten eine Remission. Im Laufe des nächsten Jahres gab es kein Rezidiv. Dieser Fallbericht deutet offensichtlich darauf hin, dass die Homöopathie als mögliche Behandlungsoption für die Behandlung von Prurigo nodularis-Fällen dienen kann.

結節性瘙癢症對順勢療法有反應的個案報告

引言: 結節性瘙癢是一種慢性良性的神經性皮炎，確切原因未知。大多數情況下，即使進行治療，結節性瘙癢（Prurigo nodularis, PN）個案也無法完全消除結節。**個案摘要:** 這是一名18歲女士的結節性瘙癢症確診個案，有一年的濕疹皮膚病史。根據症狀的整體性，處方出順勢療法藥物氯化鈉，患者的徵狀和症狀方面逐漸表現出穩定的好轉，狀況在4個月後緩解，在接下來的一年中沒有復發。該個案報告明顯表示，順勢療法可以作為結節性瘙癢個案的可能治療選擇。