



International Journal of Homoeopathic Sciences

E-ISSN: 2616-4493
P-ISSN: 2616-4485
www.homoeopathicjournal.com
IJHS 2021; 5(3): 300-305
Received: 06-05-2021
Accepted: 08-06-2021

Dr. Ruchi Singh
Associate Professor,
Department of Organon of
medicine & Homoeopathic
Philosophy, Homoeopathic
Medical College & Hospital,
Chandigarh, India

Dr. Atul Kumar Singh
Principal, Dr MPK
Homoeopathic Medical
College, Hospital and Research
Centre, Homoeopathy
University Jaipur, India

Dr. Deeksha
Assistant Professor, Dept of
FMT Bakson Homoeopathic
Medical College and Hospital,
Greater Noida, Uttar Pradesh,
India

Corresponding Author:
Dr. Ruchi Singh
Associate Professor,
Department of Organon of
medicine & Homoeopathic
Philosophy, Homoeopathic
Medical College & Hospital,
Chandigarh, India

A case series on psychophysiological dimension of *Acne vulgaris* and its homoeopathic treatment

Dr. Ruchi Singh, Dr. Atul Kumar Singh and Dr. Deeksha

DOI: <https://doi.org/10.33545/26164485.2021.v5.i3e.438>

Abstract

Background: Acne vulgaris is a common problem having psychological and emotional impact. Identifying psychological triggers of acne can help in homoeopathic medicine selection.

Methods: Five case profiles of acne vulgaris patients having psychological triggers are presented. Cases were treated with individualized homoeopathic medicine after case taking, analysis, evaluation and repertorization.

Results: Significant relief was seen in all cases with corresponding changes in Global Acne Grading System (GAGS) and ACNE-QoL scores.

Conclusion: Homoeopathic medicine selected on the basis of psychological history of patients provides benefit in cases of acne vulgaris.

Keywords: Psychological triggers, GAGS, dermatological

Introduction

The relation between mind and skin involves an underlying interaction between nervous system, skin and immunity. The relationship of clinically visible external complaints and invisible internal psychological state is one of the chief concerns of homoeopathic physician during all stages of homoeopathic treatment starting from case taking to cure and further maintenance of the state of health.

The evident interplay of mind and body has given rise to clinical specialty of Psychodermatology which addresses the interaction between mind and skin. Dermatological disorders may have their origin in psychological status of the patient or may result in psychosocial impact. The need for psychiatric consultation in general has been stressed by dermatologists. Psychological factors are important in chronic dermatologic conditions, such as eczema, prurigo, psoriasis, acne excoriee^[1, 4].

The course of many skin disorders is affected by stress and psychological events^[5, 6]. Approximately 30-40% patients seeking treatment for skin disorders have an underlying psychiatric or a psychological problem that either causes or exacerbates a skin complaint^[7].

Acne vulgaris is one of the commonest dermatological disorders encountered in adolescents and young adults. It is associated with high social, psychological and emotional effects comparable to those with patients having eczema or psoriasis and equivalent or greater levels as seen in patients with chronic disabling medical or surgical diseases (asthma, epilepsy, diabetes, back pain or arthritis)^[8, 10]. Approximately 50% patients of acne report emotional triggers^[11].

Acne is classified as psychophysiological disorder (primary skin diseases modified by psychosomatic factors) under psychodermatological classification in modern medicine. Psychodermatology, is a relatively new discipline in psychosomatic medicine. The two disciplines, focused on mind and skin, are interconnected at the embryonal level through ectoderm^[12].

Acne vulgaris is a chronic multifactorial inflammatory skin disorder affecting the pilosebaceous follicles. An alteration in the pattern of keratinization results in comedone formation, an increase in sebum production, proliferation of the bacterium *Propionibacterium acnes*, and the production of perifollicular inflammation^[13].

Among various etiology and predisposing factors of acne, psychological factors such as anxiety, stress, personality states etc. are underestimated. Acne excoriee, where patients either have only facial or predominant facial involvement, occurring or exacerbated after picking acne lesions is a variant of neurotic excoriation^[14].

Symptoms of mind and disposition are of highest importance for a homoeopathic physician while understanding disease causation, case taking, case processing and evaluating the response of a patient to treatment. Mental symptoms as guiding indications of underlying miasmatic state help to understand the aetiopathological state of the patient from homoeopathic standpoint. Significant events leading to mental states and their sequelae are among chief causations and/or aggravating modalities in individual cases. When exceptionally marked utilizing these as eliminating symptoms during repertorisation helps to pinpoint the similimum medicine of the case [15].

A case series of five cases of acne is presented in this article to emphasize the role of mentals or life space investigation in totality of symptoms for the management of acne vulgaris. Although a common complaint treated by homoeopathic physician, acne is often a tenacious and relapsing condition. A thorough differentiation of core causative mental symptoms as compared to mental symptom as a sequelae of psychosocial impact of Acne is essential during case taking and case processing.

Study setting

The cases were treated at Dr. Madan Pratap Khunteta Homoeopathic Medical College, Hospital and Research Centre, Homoeopathy University, Saipura, Jaipur.

Methods

Cases of acne vulgaris were treated with individualized Homoeopathic medicines selected after Analysis, Evaluation, constructing Totality of symptoms and Repertorization followed by due consultation of Materia Medica. Informed consent was obtained from the patients. The Homoeopathic medicines were procured from a good manufacturing practices certified company. Homoeopathic medicines were dispensed in globules of size 30, 4 pills to be taken in each dose. Change of medicine and/or dosage was done on basis of Homoeopathic principles after observing changes in symptoms of patient. Each case was followed up for a period of at least 3 months.

Assessment

Patient response was assessed using Global Acne Grading

System (GAGS) [16] and ACNE-QoL scores. Acne-QoL is a patient-completed questionnaire, composed of 19 items in four subscales: Self-Perception, Role-Emotional, Role-Social, and Acne Symptoms denoted by four domains D₁, D₂, D₃ and D₄ respectively [17, 19].

Case profiles

Case 1

An 18-year old, female presented with multiple painful papular and pustular lesions on face since 1-year which were previously treated with multiple self-prescribed topical applications unsuccessfully. Patient had marked perspiration on face and a habit of picking on lesions and scratching face specially while under stress.

Life-space and mentals

1 year back patient was in a romantic relationship but her parents forced her to discontinue her studies after knowing about it. She was sad and depressed about the incidence and since then she became reserved, irritable and anxious about her studies and had constant thoughts about her relationship and its failure.

Baseline assessment on September 18, 2017, showed GAGS score-18; ACNE-QoL- D₁-10, D₂-8, D₃-10 and D₄-10

Prescription and follow-up

On the basis of totality and repertorial analysis *Natrium muriaticum* 200 single dose, in globules, was prescribed followed by placebo for 15 days.

On the 2nd visit, the patient reported that improvement was observed and there were no new lesions and old lesions are better. The treatment was continued with a placebo for next 15 days.

Finally, lesions markedly reduced in one month but few lesions were persistent so *Natrium muriaticum* 200 single dose repeated with placebo for next 15 days on 3rd visit with marked improvement but a few new lesions appeared so *Natrium Muriaticum* 1M single dose with placebo for a week was prescribed on 4th visit, lesions completely disappeared so no medicine was prescribed afterwards. GAGS score-2; ACNE-QoL- D₁-25, D₂-20, D₃-25 and D₄-25 (November 13, 2017).

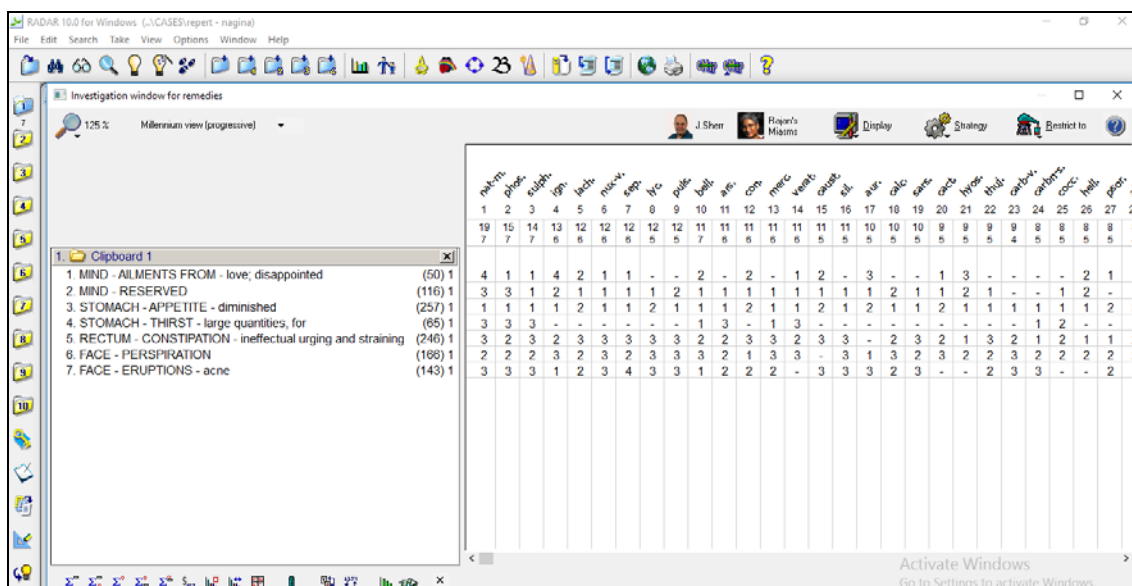


Fig 1: Repertorisation Chart of Case 1

Case 2

An 18 year old male presented with multiple itching, painful, papular, pustules and nodular lesions on face, lesions sensitive to touch, oily skin of face, and multiple ice-prick scars from 9 months.

In physical generals, he is easily chilled; doesn't feel hunger but has increased thirst so drinks often; there is craving for sweets; Constipation with insufficient, unsatisfactory stools; perspiration, offensive marked on back

Lifespace and Mentals

10 months back after passing 12th standard his family wanted him to study further but he wanted to be a part of business (Garment's shop) of his father and sit at shop. Had many arguments with parents regarding this and decided to leave studies. He felt violent anger and used to beat his younger brother many times while angry during the incidence. Since then, he became irritable and used to get angry at small issues. He was never interested in studies and

found it exerting and burden; full of laziness, no desire to do any work.

Prescription on November 06, 2017 and follow-up up to January 22, 2018

On the basis of totality and repertorial analysis *Nux vomica* 200 single dose prescribed for 15 days. GAGS score- 27; ACNE-QoL-D₁-15, D₂-12, D₃-15 and D₄-15 (November 06, 2017).

On the 2nd and 3rd visits of 15 days interval, the patient reported that improvement was observed and there were no new lesions and old lesions were better. The treatment was continued with placebo. Finally, lesions markedly reduced in one month but few lesions were persistent so *Sulphur* 200 single dose was prescribed as intercurrent medicine on 4th visit with marked improvement and lesions completely disappeared, no medicine was prescribed afterwards. GAGS score-6; ACNE-QoL- D₁-25, D₂-20, D₃-25 and D₄-25 (January 22, 2018).

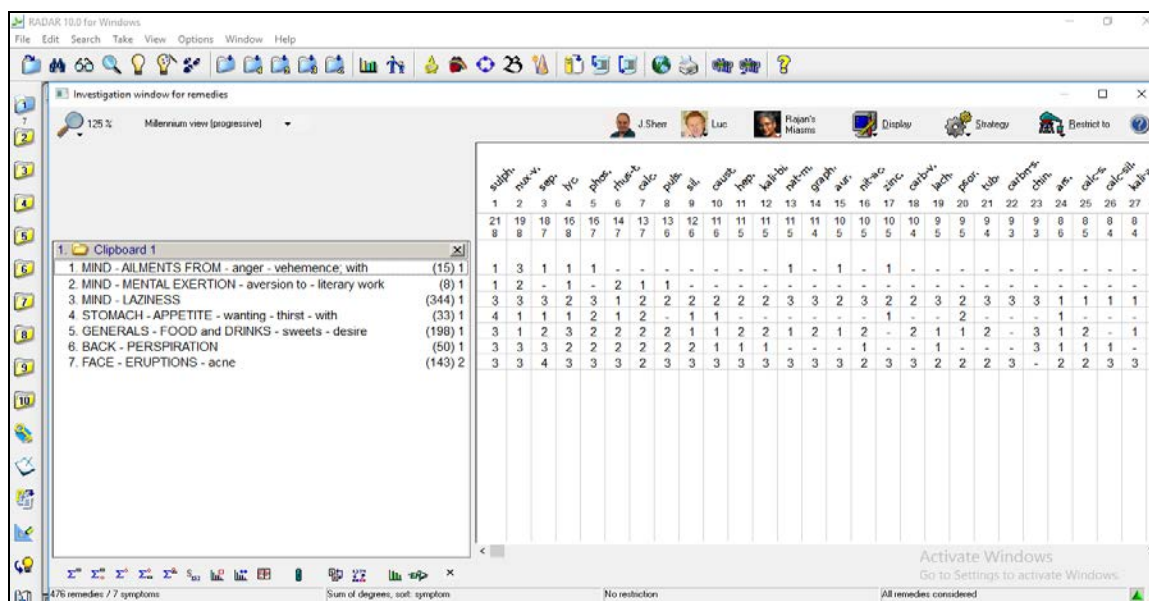


Fig 2-Repertorisation chart of Case 2

Case 3

A 22 year old male presented with multiple itching, painful, papular, pustules and nodulocystic lesions on face, lesions sensitive to touch, oily skin of face and multiple ice-prick scars from 3 years.

Physical generals: Appetite was diminished, easy satiety after few mouthfuls; thirstless; desire for spicy food.

Sexual History: Married since 4 years but has extramarital relationships with multiple partners and hides his things from wife with fear of divorce. Difficulty in erections while intercourse with increased sexual desire.

Lifespace and Mentals: 3 years back he was castoff from his job as a restaurant waiter as he was blamed for stealing things of the restaurant. He felt insulted and for 3 months he didn't join anywhere else. Since then, he doesn't talk to anyone with loud voice and became soft spoken and hesitates to take any decision.

On physician's observation: Trying to manipulate his

errors and changing statements while narrating about sexual history.

Prescription on November 18, 2017 and follow-up up to February 26, 2018

On the basis of totality and repertorial analysis *Lycopodium clavatum* 200 single dose prescribed.

GAGS score-32; ACNE-QoL- D₁-10, D₂-8, D₃-10 and D₄-10(November 18, 2017).

On the 2nd visit, the patient reported that improvement was observed and there were no new lesions and old lesions were better. The treatment was continued with placebo for next 15 days. On the 3rd visit there was status quo so *Lycopodium clavatum* 200 single dose repeated followed by placebo for next 15 days. On 4th visit there was improvement so placebo was prescribed again for next 15 days. On 5th visit lesions were again status quo so *Lycopodium clavatum* 1M single dose followed by placebo for next 15 days was prescribed and lesions completely disappeared, no medicine was prescribed afterwards. GAGS score-6; ACNE-QoL- D₁-30, D₂-24, D₃-30 and D₄-27(February 26, 2018).

Symptom	No	1	2	3	4	5	6	7	8	9	10	11	12	13	14	15	16	17	18	19	20	21	22	23	24	25	26	27
1. MIND - AILMENTS FROM - mortification (67) 1	16	13	13	13	13	12	12	11	10	10	10	9	9	8	8	8	8	7	7	7	7	7	6	6	6	6	6	6
2. MIND - LIAR (31) 1	7	7	7	7	5	6	6	6	5	5	5	5	5	5	5	5	4	4	4	4	5	5	5	4	5	4	4	4
3. STOMACH - THIRSTLESS (179) 1	1	1	1	1	1	1	1	1	1	1	1	1	1	1	1	1	1	1	1	1	1	1	1	1	1	1	1	1
4. STOMACH - APPETITE - easy safety (106) 1	2	2	2	2	3	2	2	1	1	2	1	1	1	1	1	1	1	1	1	1	1	1	1	1	1	1	1	1
5. GENERALS - FOOD and DRINKS - spices - desire (83) 1	1	1	2	1	3	3	2	2	2	2	2	1	1	1	1	1	1	1	1	1	1	1	1	1	1	1	1	1
6. MALE GENITALIA/SEX - SEXUAL DESIRE - increased - erect. (58) 1	3	2	2	2	1	2	2	1	2	3	1	2	2	2	2	2	1	3	2	2	2	1	1	1	1	1	1	1
7. FACE - ERUPTIONS - acne (143) 1	3	3	3	4	3	3	3	2	2	2	2	2	2	2	2	2	3	1	3	1	3	3	2	2	3	3	2	2

Table 3: Repertorisation chart of Case 3

Case 4

A 25 year old female presented with multiple itching, painful, papular, pustules and nodular lesions on face, unhealthy, greasy skin of face from 5 years.

Physical generals: Thirstless; Constipation with no urging, passes painful hard stools in 2 days; and sleep disturbed due to constant thinking while lying for sleep.

Sexual History

Married since 6 years with history of marital sexual abuse. Pain during and after intercourse.

Gynaecological and obstetrics history

Cycle-Regular, 4/28-30 Days.
Discharge per vagina-Thick, white, with itching in vulval region.
Obstetrics history-G₃P₃A₀L₃

Lifespaces and Mentals

5 years back her husband left the job (fruits hawker) and started excessive alcohol drinking and abusing her physically and sexually and she felt angry with herself but never expressed. She started working as tailor for earning

but her husband never supported her.

She is reserved and shy and keeps things to herself only and blames herself for not being strong enough to resist.

Prescription on January 26, 2018 and follow-up up to April 9, 2018

On the basis of totality and repertorial analysis *Staphysagria* 200 single dose prescribed. GAGS score-30; ACNE-QoL- D₁-15, D₂-12, D₃-15 and D₄-15(January 26, 2018).

On the 2nd and 3rd visit, the patient reported that improvement was observed and there were no new lesions and old lesions were better. The treatment was continued with placebo for one month. However, no significant change was observed on the 4th visit. After reconsidering the case, *Staphysagria* 200 single dose was repeated with placebo for next 15 days. On 5th visit there was improvement so placebo was prescribed again for next 15 days. On 6th visit there were few new lesions and old lesions were same, therefore *Staphysagria* 1M single dose with placebo for next 15 days was prescribed. On 7th visit lesions remitted therefore no medicine was prescribed afterwards. GAGS score-12; ACNE-QoL- D₁-30, D₂-24, D₃ -30 and D₄ -27(April 9, 2018).

Symptom	ovale	straght	sup	retrom	plike	comp	suph	lady	micro	ph-pho	kal-ic	anthy	ovic	nit-w	ovic	ovic	ovic	ovic	ovic	ovic	ovic	ovic	ovic	ovic	ovic	ovic	ovic	ovic
1. MIND - AILMENTS FROM - abused; after being (8) 1	1	2	3	4	5	6	7	8	9	10	11	12	13	14	15	16	17	18	19	20	21	22	23	24	25	26	27	
2. MIND - EMOTIONS - suppressed (15) 1	1	3	1	1	1	1	1	1	1	1	1	1	1	1	1	1	1	1	1	1	1	1	1	1	1	1	1	1
3. MIND - REPROACHING himself (69) 1	1	1	1	1	1	1	1	1	1	1	1	1	1	1	1	1	1	1	1	1	1	1	1	1	1	1	1	1
4. STOMACH - THIRSTLESS (179) 1	1	2	2	1	3	2	1	1	1	3	2	1	1	1	1	1	1	1	1	1	1	1	1	1	1	1	1	1
5. RECTUM - CONSTIPATION - difficult stool (198) 1	3	1	3	2	3	3	3	2	1	2	1	1	1	1	1	1	1	1	1	1	1	1	1	1	1	1	1	1
6. FEMALE GENITALIA/SEX - LEUKORRHEA - itching (39) 1	2	1	3	2	1	1	1	1	2	1	1	2	1	1	1	1	1	1	1	1	1	1	1	1	1	1	1	1
7. FACE - ERUPTIONS - acne (143) 1	3	4	3	3	2	3	2	2	2	2	1	1	1	3	3	2	3	2	3	2	2	2	2	2	3	1	1	1

Table 4: Repertorisation chart of Case 4

Case 5

A 20 years old female presented with multiple itching, painful comedones, papulo-pustular and nodular lesions on face from 2 years.

Physical generals- Thirstless with dryness of lips; Desire for fried, fatty food with causes diarrhea and pain in abdomen;

Menstrual history

Menarche-15 years, late, had taken medicines initially for 2 years for regularizing cycle.
Cycle-Regular-/28-32 Days NAC.

Lifespac and Mentals

2 years back her education was discontinued. She felt like there is nobody in her life who love her and care for her. She was stressed and felt sad, felt like crying and weeping all the time (even while narrating the incidence she was tearful) about the incidence, since then she became very

emotional, sensitive and gets hurt easily. She always needs someone to talk to her and listen to her.

Prescription on November 18, 2017 and follow-up up to January 27, 2018

On the basis of totality and repertorial analysis *Pulsatilla nigricans* 200 single dose prescribed with placebo for 15 days. GAGS score-26; ACNE-QoL- D₁-10, D₂-8, D₃-10 and D₄-10 (November 18, 2017).

On the 2nd and 3rd and 4th visit, the patient reported that improvement was observed and there were no new lesions and old lesions were better. The treatment was continued with placebo for 2 months. On the 5th visit there was status quo so *Pulsatilla nigricans* 200 single dose was repeated with placebo for next 15 days. On 6th visit there was improvement so placebo was prescribed again for next 15 days and thereafter lesions remitted therefore no medicine was prescribed afterwards. GAGS score-4; ACNE-QoL- D₁-25, D₂-20, D₃-25 and D₄-25(January 27, 2018).

Table 5-Repertorisation chart of Case 5

Conclusion

Life span investigation forms a major part of homoeopathic case taking. Identifying potential triggers and emotional symptoms of patients help in finding the similimum. The present case series shows the role of psychological symptoms and history in homeopathic medicine selection and cure. Individualized homoeopathic medicine showed positive results in all cases. Acne has multifactorial etiology. A patient centric approach for finding the homoeopathic similimum gives benefit to patient.

Homoeopathic treatment involves a deeper understanding of each case in a wholistic, individualistic and dynamic manner. This case series shows the potential benefit of homoeopathy in cases of acne vulgaris. Future studies on role of homoeopathy in disorders having prominent psychological causes are warranted.

References

- Jafferany M. Psychodermatology: a guide to understanding common psychocutaneous disorders. Prim Care Companion J Clin Psychiatry 2007;9(3):203-213.

- Humphreys F, Humphreys MS. Psychiatric morbidity and skin disease: what dermatologists think they see? Br J Dermatol 1998;139:679-681. [PubMed] [Google Scholar]
- Attah Johnson FY, Mostaghimi H. Comorbidity between dermatologic diseases and psychiatric disorders in Papua New Guinea. Int J Dermatol 1995;34:244-248. [PubMed] [Google Scholar]
- Capoore HS, Rowland Payne CM, Goldin D. Does psychological intervention help chronic skin conditions? Postgrad Med J. 1998;74:662-664.[PMC free article] [PubMed] [Google Scholar]
- Humphreys F, Humphreys MS. Psychiatric morbidity and skin disease: What dermatologists think they see. Br J Dermatol 1998;139:679-81. [PUBMED]
- Capoore HS, Rowland Payne CM, Goldin D. Does psychological intervention help chronic skin conditions? Postgrad Med J 1998;74:662-4. [PUBMED]
- Picardi A, Abeni D, Melchi CF, Puddu P, Pasquini P. Psychiatric morbidity in dermatological outpatients: An issue to be recognized. Br J Dermatol 2000;143:983-91.

8. Gupta MA, Gupta AK. The use of antidepressant drugs in dermatology. JEADV [Internet]; 2001;15:512-518. Available from: <https://www.deepdyve.com/lp/wiley/the-use-of-antidepressant-drugs-in-dermatology-FNf4Q19I6p>.
9. Jones-Caballero M, Chren MM, Soler B, Pedrosa E, Peñas PF. Quality of life in mild to moderate acne: Relationship to clinical severity and factors influencing change with treatment. J Eur Acad Dermatol Venereol [Internet]; 2007;21:219-26. Available from: <https://www.ncbi.nlm.nih.gov/pubmed/17243958>
10. Kubba R, Bajaj AK, Thappa DM, Sharma R, Vedamurthy M, Dhar S, *et al.* Indian Acne Alliance (IAA) Acne in India: Guidelines for management Iaa consensus document Genetics in acne Acne and quality of life Pathogenesis of acne. Indian J Dermatol Venereol Leprol [Internet]; 2009;75:S4-5. Available from: <https://www.ncbi.nlm.nih.gov/pubmed/19282578>
11. Cotterill JA. Psychophysiological aspects of eczema. Semin Dermatol. 1990;9:216-219. [PubMed] [Google Scholar]
12. Koo JY, Lee CS. General approach to evaluating psychodermatological disorders. In: Koo JY, Lee CS, editors. Psychocutaneous Medicine. New York, NY: Marcel Dekker, Inc 2003, 1-29.
13. Hanna S, Sharma J, Klotz J. Acne vulgaris: more than skin deep. Dermatol Online [Internet]; 2003;9(3):8. Available from: <https://www.ncbi.nlm.nih.gov/pubmed/12952755>
14. Yadav S, Narang T, Kumaran M S. Psychodermatology: A comprehensive review. Indian J Dermatol Venereol Leprol 2013;79:176-92
15. Hahnemann S. Organon of Medicine. 5th & 6th ed. New Delhi: B Jain Publishers 1982.
16. Doshi A, Zaheer A, Stiller MJ. A comparison of current acne grading systems and proposal of a novel system. Int J Dermatol 1997;37:416-8
17. Girman CJ, Hartmaier S, Thiboudot D, Johnson J, Barber B, DeMuro-Mercon C, *et al.* Evaluating health related quality of life in patients with facial acne: Development of a self-administered questionnaire for clinical trials. Qual Life Res 1996;5:481-90.
18. Martin AR, Lookingbill DP, Botek A, Light J, Thiboudot D, Girman CJ. Health related quality of life among patients with facial acne—assessment of new acne specific questionnaire. Clin Exp Dermatol 2001;26:380-5.
19. Fehnel SE, McLeod LD, Brandman J, Arbit DL, MC Laughlin-Miley CJ, Coombs JH, *et al.* Responsiveness of Acne Specific Quality of Life Questionnaire (Acne-QoL) to treatment for acne vulgaris in placebo-controlled clinical trials. Qual Life Res 2002;11:809-16.